



Pain Relief

Dr.
M.B.B.S.,
Radiology

Dr.

MOHAN ADVANCE DIAGNOSTIC CENTRE

MOHAN X-RAYS

MOHAN PATHOLOGY LAB

1.5 TESLA M.R.I.

16 SLICE CT SCAN



DIGITAL & PLAIN X-RAY, ULTRASOUND, COLOUR DOPPLER & PATHOLOGY

A-14, Gandhi Nagar, Opp. City Station, Near Roadways Bus Stand, Rampur Road, Moradabad-244001

Mob.: 9219558663, 9219558664

Dr. Ram Mohan Agarwal

Dr. (Mrs.) Rekha Agarwal

Dr. Rajat Agarwal

M.B.B.S., F.C.G.P., F.I.C.N., D.M.R.E. (Gold Medalist)
M.R.I.A., M.I.C.R., M.I.F.U.S.M.B. (Radiologist & Sonologist)
SENIOR C.T., M.R.I. & U.S. SPECIALIST
Professionally Trained AT : S.G.P.G.I (Lucknow)
P.G.I (Chandigarh), A.I.I.M.S., M.A.M.C. (Delhi)
J.K. Institute of Radiology & Cancer Research (Kanpur)

M.B.B.S., D.G.O., P.G.D.C.P., M.I.F.U.S.M.B.

M.B.B.S., M.D. (Radiodiagnosis)

Dr. (Mrs.) Priya S. Agarwal

M. D. Pathology

NAME: MAST. ARHAN AGE/SEX. 13 YRS/M.C. DR-71

REFBY: DR. CHANDRA VIBHASH

DATE: 01.07.2024

PART X-RAYED: - BARIUM ENEMA EXAMINATION.

- (1) IMMEDIATE PICTURE A.P. VIEW.
- (2) 5 MTS PICTUR AFTER GIVING MORE ENEMA A.P. VIEW.
- (3) LATERAL VIEW.
(Digital computerized radiogram)

- Barium head has reached rectum, sigmoid colon and adjacent part of colon (? descending colon). These parts are seen extending upwards and anteriorly in right side of abdomen and towards left side at the level of L1-L2 vertebrae.
- Beyond this level no barium is seen.
- No barium is seen in cap. of abdominal opening suggesting that distal loop is not patent.

DR. RAJAT AGARWAL
M.B.B.S., M.D. Radiodiagnosis
Consultant Radiologist

DR. RAM MOHAN AGARWAL
M.B.B.S., F.C.G.P., F.I.C.N., D.M.R.E.
Radiologist (Gold Medalist)

- NOTE** • These Findings should always be considered in correlation with the Clinical and other Investigation findings
- Discourage Sex Determination to Stop Female Feticide.
 - **NOT FOR MEDICOLEGAL PURPOSES**
 - Please don't leave the films exposed to Sunlight



SIGMOIDOSCOPY

Patient Name : MASTER ARNAM
Referred By : SELF

Age/Gender : 13 Years/Male
Unit No :

Date : 01-Jul-24

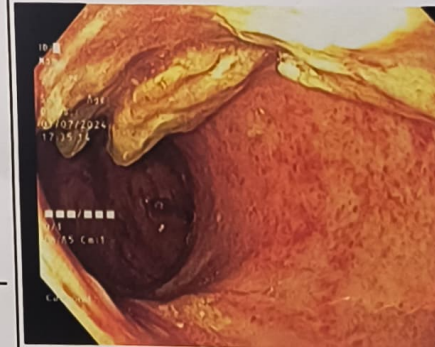
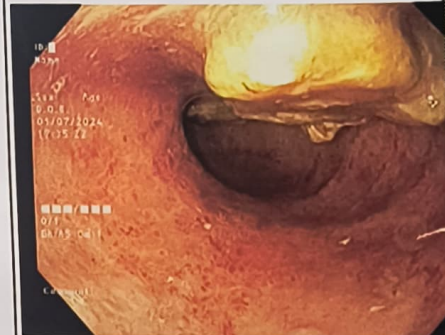
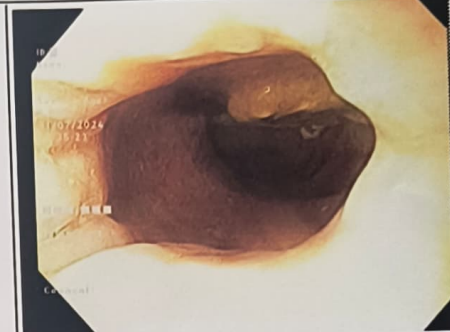
MEDICATIONS : Nil

PROCEDURE : Flexible sigmoidoscopy.

INSTRUMENT : Flexible sigmoidoscopy.

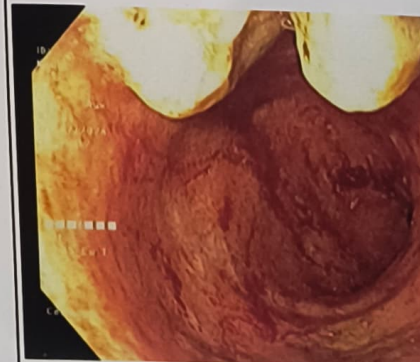
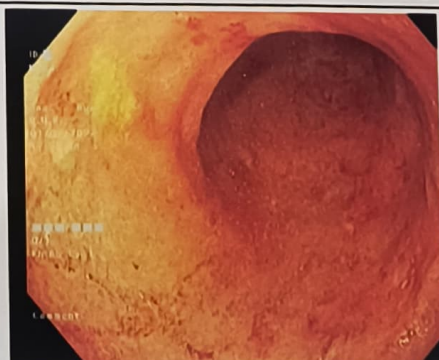
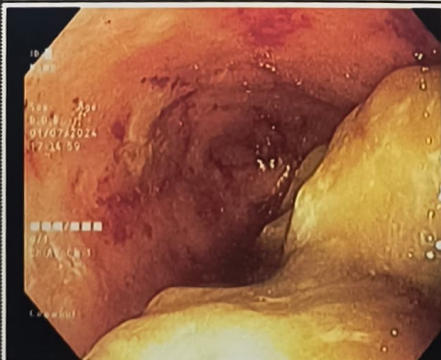
Colonoscope passed till end of closed colonic pouch (likely at the level of distal descending colon). Suboptimal bowel preparation. Mucosa was visualized through repeated washing and suctioning. Visualized mucosa in sigmoid colon and rectum appears edematous, erythematous with multiple erosions. No haemrrhoid is seen.

IMPRESSION : POST COLOSTOMY STATUS
? DIVERSION COLITIS



DR. ARUN KUMAR VARSHNEY

MD(MEDICINE), DNB(GASTROENTEROLOGY)
DEPT. OF GASTROENTEROLOGY AND HEPATOLOGY



1/10/24, 21/10, 21/10

(204)

1052/24

ओ. पी. डी. पर्ची / OUT PATIENT TICKET

क.स.बा.अ.-13 (संशोधित)
KSCH-13 (Improved)

कलावती सरन बाल अस्पताल, नई दिल्ली

KALAWATI

Kalawati Saran Children Hospital New Delhi

Master. ARHAM / Male / 13 years 0 months 0 days 0 hours 0 mins

Paediatric Surgery / Room-204 / Token-1

Mobile No:*****950

DAYS:TUE,THU,SAT

UHID:20240021041



07-10-2024 08:17:26 AM

दिनांक / Date.....

ओ. पी. डी. पंजी. सं. / O.P.D.

नाम / Name

टीकाकरण विवरण / Immunizat

हेपेटाइटिस-बी, पोलियो Hep-B, OPV at Birth	
बी.सी.जी. BCG	
डी.पी.टी., पोलियो, हेपेटाइटिस-बी DTP, Polio, Hep-B 1 st	
डी.पी.टी., पोलियो, हेपेटाइटिस-बी DTP, Polio, Hep-B 2 nd	
डी.पी.टी., पोलियो, हेपेटाइटिस-बी DTP, Polio, Hep-B 3 rd	
खसरा एवं विटामिन ए Measles Vitamin-A	
एमएमआर MMR	
डी.पी.टी. पोलियो (1 बूस्टर खुराक) DTP, Polio (1 Booster)	
टाइफाइड का टीका Typhoid	
डी.पी.टी./ ओ.पी.वी-(2 बूस्टर) DTP, Polio (2 Booster)	
अन्य Others	

Flute Traumatic
Perforation to Abscess
in sacral region

- End Sigmoid colostomy

+ Abscess drainage

to JHA on 17/10/24

LL2:

wound is

दिनांक / Date.....

डॉक्टर के हस्ताक्षर / Signature of Doctor

(Sacrococcygeal

region)
- minimal drainage

ओ.पी.डी. पंजीकरण सं.

प्रारम्भिक निदान पर्चा

केवल अस्पताल के प्रयोग के लिए

O.P.D. Reg. No.

Provisional Diagnosis Slip

For Hospital Use Only

दिनांक

Date

Plan : EUA before stoma
closure.

Patient had previous no multiple
transfusion

Alo :

To attend Paediatric medicine
for ^{no} multiple transfusion for
reduced hemoglobin @

(for further workup)

(105-109)

- wound dressing + 210

Bhargava
SPD

दिनांक

Date

18 APR 2024

35 kgs

F/U/c/o End sigmoid colectomy + sacral
abscess drainage done for Traumatic
rectal perforation. - 17/2/24

no flush c/o.

no pre-stomal ulceration.

P/A: stoma functional, pre-stomal ulceration.

HE: healthy granulation tissue. ± slough

Adv: ASD - 210

◦ Stoma bag - (210) / PSW-4

◦ Syp MVI 1 tsf OD X 2 weeks

◦ Stoma paste / stoma powder - (210)

◦ Silodum ointment LA 5D

◦ F/U after 1 month.

Pete-i



Government of India



अरहम

Arham

जन्म तिथि / DOB : 10/05/2006

पुरुष / Male




4178 2603 6998

मेरा आधार, मेरी पहचान



भारत सरकार

Government of India



परवेज

Parvej

जन्म तिथि / DOB : 01/01/1979

पुरुष / Male



4650 2180 2552

आधार - आम आदमी का अधिकार



भारतीय विशिष्ट पहचान प्राधिकरण

Unique Identification Authority of India

पता:

संबोधित: कमर खाँ, शोकत अली
मार्ग, रामपुर सिटी, रामपुर, रामपुर,
उत्तर प्रदेश, 244901

Address:

S/O: Kamar Khan, shokat ali
marg, Rampur City, Rampur,
Rampur, Uttar Pradesh, 244901

4650 2180 2552



1947

1800 300 1947



help@uidai.gov.in

WWW

www.uidai.gov.in

ABHISHIKHA TRUST

S. No. 17.....

Date: 06/07/2024

सेवा में,

श्रीमान दूसरी महोदय जी
Abhishikha Trust
G-3, Gali No. - 7 Pusta
Sonia Vihar; Delhi - 110094

माहिकम,

मैं दिल्ली के कलावली अस्पताल में
अपने लड़के को भर्ती करा रहा हूँ जिसका
नाम अरुण है। और मेरा नाम पबनेज है
गार्ड में इसके घेरे और पिछे लोडिंग
करने के रास्ते में इन्फेक्शन बताया है।
इसके इलाज में बहुत पैसा लगा रहा है
और मेरी नजरि भी छुट गई है। इसी
के कारण खाने पाने की भी दिक्कत समार्या है।
क्रिया करने हमारी मदद करे मैं आपका बहुत
बहुत आभारी रहूंगा

परनेज



Office Address : G-3, Gali No. 7, Pusta, Sonia Vihar, Delhi-110094

Website : www.abhishikha.org E-mail ID : info@abhishikha.org

Contact No. : 9958524587